

# Prenatal Diagnosis and Outcomes of Cervical Meningocele and Myelomeningocele

CME  
CreditsAn-Shine Chao<sup>1,2</sup>, Lan-Sin Jhang<sup>1,2</sup>, Peter Ching-Chang Hsieh<sup>1,2\*</sup><sup>1</sup>Department of Obstetrics and Gynecology, New Taipei Municipal Tucheng Hospital, New Taipei, Taiwan, <sup>2</sup>Department of Obstetrics and Gynecology, Chang Gung Memorial Hospital and University, Taoyuan, Taiwan

## Abstract

Prenatal diagnosis of myelomeningocele remains challenging for obstetricians, ultrasonographers, and radiologists, although the increased maternal serum alpha-fetoprotein level aids in the confirmative diagnosis. Fetal cervical myelomeningocele and meningocele are very rare and unique types of myelomeningocele. Prenatal diagnosis of cervical myelomeningocele and meningocele should include the differential diagnosis and association of many intracranial and spino-skeletal pathogenetic variants and genetic diseases, including subependymal nodular heterotopia and Klippel–Feil syndrome. In this report, a comprehensive review of fetal cervical myelomeningocele with its prenatal diagnosis and long-term outcomes is presented.

**Keywords:** Cervical meningocele, cervical myelomeningocele, magnetic resonance imaging, prenatal diagnosis, ultrasonography

## INTRODUCTION

Prenatal diagnosis of spinal dysraphism, which mostly manifests as myelomeningocele, remains challenging for obstetricians, ultrasonographers, and radiologists. Elevated maternal serum concentrations of alpha-fetoprotein are an indicator of open spinal dysraphism. High-resolution ultrasound and magnetic resonance imaging (MRI) modalities aid in the diagnosis of spinal dysraphism.

The incidence of spinal dysraphism is approximately 1–2/1000 live births. Approximately 80% of spinal dysraphism occurs in the lumbosacral region, followed by the lumbar, thoracic, sacral, and cervical regions.<sup>[1,2]</sup> Spinal dysraphism is commonly identified based on the presence of open lesions, maternal alpha-fetoprotein levels, and early trimester ultrasound imaging. Fetal surgery has evolved to improve perinatal outcomes. For example, hydrocephalus-related complications have decreased.<sup>[1–4]</sup> The incidence of cervical lesions is estimated at 1 in 50,000 live births (1%–5%) among all cases of spinal dysraphism. Cervical myelomeningocele and meningocele are unique forms of spinal dysraphism, and they have several characteristic features, a distinct postnatal course, and are different from lumbosacral myelomeningocele.<sup>[4–7]</sup>

## DIFFERENTIAL DIAGNOSIS

Cervical myelomeningocele and meningocele, similar to the lower lumbar-sacral defect, result from an early neural developmental anomaly and lead to various structural abnormalities that are often accompanied by functional neurological deficits. The unique appearance of the site presents a challenge in distinguishing cervical myelomeningocele and meningocele from other superficial skin lesions, such as cystic hygroma, hemangioma, dermoid cyst, hemangiolymphangioma, epidermal scalp cyst, and branchial cleft cyst.<sup>[3,8]</sup>

## IMAGING MODALITY

Ultrasound is an effective prenatal screening tool for the early detection and differential diagnosis of various lesions, including those mentioned in the preceding section. In the late

**Address for correspondence:** Dr. Peter Ching-Chang Hsieh,

Department of Obstetrics and Gynecology, New Taipei Municipal Tucheng Hospital, New Taipei, Taiwan.

Department of Obstetrics and Gynecology, Chang Gung Memorial Hospital and University, Taoyuan, Taiwan.

E-mail: doctor77@cgmh.org.tw

Received: 30-04-2023 Accepted: 03-05-2023 Available Online: 10-01-2024

### Access this article online

Quick Response Code:



Website:  
<https://journals.lww.com/jmut>

DOI:  
10.4103/jmu.jmu\_51\_23

This is an open access journal, and articles are distributed under the terms of the Creative Commons Attribution-NonCommercial-ShareAlike 4.0 License, which allows others to remix, tweak, and build upon the work non-commercially, as long as appropriate credit is given and the new creations are licensed under the identical terms.

For reprints contact: WKHLRPMedknow\_reprints@wolterskluwer.com

**How to cite this article:** Chao AS, Jhang LS, Hsieh PC. Prenatal diagnosis and outcomes of cervical meningocele and myelomeningocele. *J Med Ultrasound* 2024;32:21-4.

1980s, the accurate detection of cervical myelomeningocele and meningocele was performed by using cranial and spinal computed tomography (CT) or MRI.<sup>[9,10]</sup> MRI can assist in distinguishing between different types of lesions and in identifying associated anomalies in both intracranial and spinal regions.<sup>[11-13]</sup> The recognition of associated anomalies is crucial for perinatal counseling and for planning effective treatment. This review is a collection of cases reported after CT and MRI neuroimaging are implied in the diagnosis [Table 1].

## CLASSIFICATION AND NOMENCLATURE

The classification of cervical cystic lesions is under debate.<sup>[14]</sup> In 1985, McLone and Naidich defined terminal sacral myelomeningocele as a type of closed spinal dysraphism characterized by a skin-covered mass in the posterior midline, along with a narrow posterior spina bifida and a cyst containing cerebrospinal fluid.<sup>[15]</sup> In the early 1990s, Steinbok and Cochrane proposed the hypothesis of limited dorsal myeloschisis and categorized myelomeningocele into

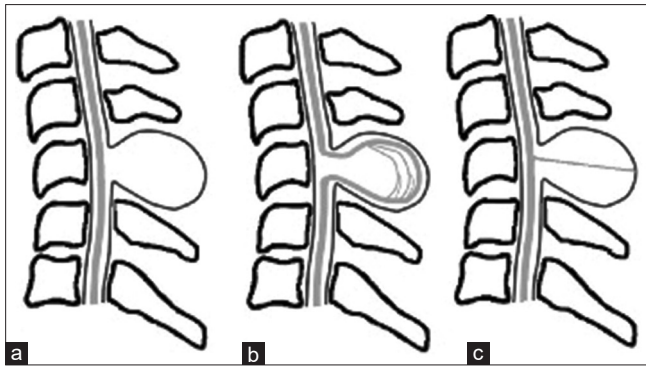
two types: meningocele and myelocystocele.<sup>[6]</sup> The authors hypothesized that these cervical defects are part of a spectrum of one underlying developmental abnormality known as limited dorsal myeloschisis, with the eventual abnormality depending on the presence or absence of associated hydromyelia.

Subsequently, additional classifications were made based on the bone structural or neurological components. Pang and Dias proposed a classification system based on the internal structure of the cystic lesions, dividing them into limited dorsal myeloschisis containing a fibroneurovascular stalk in a dural sac and split cord malformations containing two hemicords in a dural sac.<sup>[16]</sup> In a case series, Salomão *et al.* divided these into (1) cystic spinal dysraphism of the cervical and upper thoracic regions with a stalk of neuroglial or fibrovascular tissue, (2) myelocystocele consisting of a second ependymal-lined cyst herniated inside a meningocele, and (3) cystic spinal dysraphism of the cervical and upper thoracic regions without a stalk or true meningocele [Figure 1].<sup>[17]</sup> Habibi *et al.* and Tortori-Donati *et al.* classified cervical

**Table 1: Summary of published case reports of cervical myelomeningocele and meningocele**

Author	Year	Number of cases	Gender	Age at diagnosis	Associate anomaly	Outcomes
Delashaw <i>et al.</i>	1987	4	Female	NB	One hydrocephaly, one KFS	Hydrocephaly: Walk with assistance, poor bladder, and bowel control
Steinbok	1991	8	NA	NB	3 hydrocephaly	4 motor deficit
Bhargava	1992	1	Male	Prenatal at 24 weeks	Neck mass only	Well
Pang	1993	9	NA	Infants		6 motor deficit
Ankola PA	1998	1	Female	NB	Neck mass only	Well
Pérez	2000	11	7 females 4 males	Infants - adults	5 hydrocephaly	Anomalies
Sun CL	2000	8		One day - 9 months	5 hydrocephaly	4 motor deficit
Nishio	2001	2	Female	NB	One hydrocephaly	Well One no operate
Meyer Heim	2003	5	NA	Infants	One open type	One behavior problem
Feltes	2004	1	Female	NB		Well
Habibi	2006	16	9 males	1 day - 4 months	Open type	2 under performance
	2010	1	6 females	NB		NA
Salomao	2006	18	NA	Infants - adults		One fatal 3 under performance 2 behavior problem
Wang HK	2006	1	Female	Infant		Well
Kasliwal MK	2007	10	5 females 5 males	Infants - child		NA
Ali	2009	8	2 females 6 males	Infants - child	One double MMC	Paraplegic in double MMC
Parthasarathy S	2012	1		NB		NA
Lotfi	2012	1	Male	NB		Well
Srihari	2013	1	Female	NB	Anterior MMC	Expired
Pessoa	2015	1	Female	NB		Well
Burnol	2015	1	Female	NB		Well
Kırbaş	2015	1	Male	Prenatal at 23 weeks		Well
Shamji	2015	1	Female	Adult		Well
Kamalammal	2016	1	NA	NB		NA
Sriharsha R	2020	1	Male	Infant		NA
Chao	2023	1	Female	Prenatal at 33 weeks	Hydrocephaly	Under performance

KFS: Klippel-Feil syndrome, MMC: Meningocele, NA: Not available, NB: Newborn



**Figure 1:** Classification of cervical myelomeningocele and meningocele. (a) Fibrovascular or neuroglial tissue protruding from the posterior surface of the spinal cord attached to the sac wall. (b) Ependymal-lined cyst that herniates inside the meningocele, representing the hydromyelic canal in connection with the outer cyst. (c) True meningocele in which meningeal tissue herniates through the defect and sac contains only cerebrospinal fluid<sup>[17]</sup>

myelomeningocele into two types: fibroneurovascular stalks and myelocystocele.<sup>[18,19]</sup>

## ASSOCIATED ANOMALIES OF CERVICAL MYELOMENINGOCELE AND MENINGOCELE

Hydrocephalus, Chiari malformations, tethered spinal cord, hydromyelia, diastematomyelia, and thickened filum terminal are commonly associated with cervical myelomeningocele and meningocele. The clinical neurological signs and symptoms of these anomalies change over time, depending on the severity of the anomaly. Incomplete division of the cervical spinal cord, thoracic hemivertebra, C1 to C2 subluxation, subependymal nodular heterotopia, and Klippel–Feil syndrome is less frequently reported anomalies associated with cervical myelomeningocele and meningocele.<sup>[20–25]</sup>

Rare types of cervical dysraphism include anterior and lateral cervical meningocele and double cervical and lumbosacral meningocele. Double cervical and lumbosacral meningocele can be identified during childhood,<sup>[26,27]</sup> whereas anterior and lateral cervical meningocele is mainly diagnosed in adulthood, except for a few cases in which meningocele was detected in newborns with torticollis.<sup>[28]</sup> Neurofibromatosis, an autosomal-dominant hereditary disease, is associated with mesodermal dysplasia and dural ectasia and is a risk factor for anterior cervical meningocele.<sup>[25,26,28,29]</sup>

## PRENATAL OR NEONATAL DIAGNOSIS OF CERVICAL MYELOMENINGOCELE AND MENINGOCELE

Myelomeningocele may be induced by the nonclosure of the fetal neural tube and not by rupture once it is closed.<sup>[30,31]</sup>

The first case of prenatal cervical myelomeningocele or meningocele was reported in 1992, in which the diagnosis was made in the 24<sup>th</sup> week of gestation (Bhargava 1992). In subsequent reports, diagnoses were made at various gestational

ages, ranging from 21 to 33 weeks [Table 1].<sup>[32,33]</sup> Meningoceles usually enlarge slowly during gestation, reaching an average size of 5 cm at birth. The protruding lesions are usually covered with intact skin. The lesions may arise from the upper cervical region spanning C1 to T1 and typically do not result in neurological deficits during neonatal life. Some cases involved mild hydrocephaly, and fetal surgery was not required. No family history of cervical myelomeningocele and meningocele was reported. Cesarean section was the preferred delivery method even though most cases that went undiagnosed resulted in uncomplicated vaginal deliveries. A well-covered mass protruding from the skin is not always indicative of cervical meningocele or myelomeningocele at birth.<sup>[34]</sup> Diagnosis in the prenatal or postnatal stage depends on the awareness and manifestation of symptoms.

## TREATMENT AND OUTCOMES: NEONATAL VERSUS LATER LIFE

From clinical and surgical perspectives, cervical myelomeningocele and meningocele have much more positive outcomes compared with thoracolumbar and lumbosacral meningocele. Few studies investigated the long-term neurocognitive effects of cervical myelomeningocele and meningocele. Individuals with hydrocephalus are at higher risk of impaired cognitive development than those with cervical myelomeningocele and meningocele.<sup>[17,24,35–38]</sup> Unlike thoracolumbar and lumbosacral lesions, cervical lesions require surgery for two reasons: prevention of future neurological deterioration caused by the released tethered elements and for cosmetic reasons. The tethered cord should be suspected when cervical meningocele is present without signs of neurological impairment. Surgical excision of the meningocele and intradural exploration to untether the spinal cord is essential for preventing neurological deterioration later in life.<sup>[22]</sup> Leakage of the cerebrospinal fluid, severe hydrocephalus, or the presence of a Chiari II malformation among neonates warrants urgent surgical planning with complete central nervous system imaging.

Part of the content was presented at the 15<sup>th</sup> Congress of the Asian Federation of Society and Biology on November 11–13, 2022, in Hyderabad, India.

## Financial support and sponsorship

This work was supported by a research grant from New Taipei Municipal Tucheng Hospital and Chang Gung Memorial Hospital, Taiwan (CORPVVL0021).

## Conflicts of interest

Prof. Peter Ching-Chang Hsieh, an editorial board member at *Journal of Medical Ultrasound*, had no role in the peer review process of or decision to publish this article. The other authors declared no conflicts of interest in writing this paper.

## REFERENCES

1. Masini L, De Luca C, Noia G, Caruso A, Lanzone A, Rendeli C, *et al.*

- Prenatal diagnosis, natural history, postnatal treatment and outcome of 222 cases of spina bifida: Experience of a tertiary center. *Ultrasound Obstet Gynecol* 2019;53:302-8.
2. Cunningham FG, Leveno KJ, Dashe JS, Hoffman BL, Spong CY, Casey BM. Acknowledgments. In: *Williams Obstetrics*, 26e. New York, NY: McGraw Hill; 2022.
  3. Chen CP. Syndromes, disorders and maternal risk factors associated with neural tube defects (I). *Taiwan J Obstet Gynecol* 2008;47:1-9
  4. Lin TY, Sung CA, Shaw SW. The application of clinical ultrasound in fetal therapy. *J Med Ultrasound* 2021;29:1-2.
  5. Warthen RO, Lo Presti JM, Burdick WF. Spina bifida cystica; review of 70 cases with report of a case of cervical meningocele. *Med Ann Dist Columbia* 1949;18:298-301.
  6. Steinbok P, Cochrane DD. The nature of congenital posterior cervical or cervicothoracic midline cutaneous mass lesions. Report of eight cases. *J Neurosurg* 1991;75:206-12.
  7. Kıymaz N, Yılmaz N, Güdü BO, Demir I, Kozan A. Cervical spinal dysraphism. *Pediatr Neurosurg* 2010;46:351-6.
  8. Chandra RV, Kumar PM. Cervical myelocystocele: Case report and review of literature. *J Pediatr Neurosci* 2011;6:55-7.
  9. Aubin ML, Vignaud J, Jardin C, Bar D. Computed tomography in 75 clinical cases of syringomyelia. *AJNR Am J Neuroradiol* 1981;2:199-204.
  10. Lee BC, Zimmerman RD, Manning JJ, Deck MD. MR imaging of syringomyelia and hydromyelia. *AJR Am J Roentgenol* 1985;144:1149-56.
  11. Andronikou S, Wieselthaler N, Fieggen AG. Cervical spina bifida cystica: MRI differentiation of the subtypes in children. *Childs Nerv Syst* 2006;22:379-84.
  12. Kunpalin Y, Richter J, Mufti N, Bosteels J, Ourselin S, De Coppi P, *et al.* Cranial findings detected by second-trimester ultrasound in fetuses with myelomeningocele: A systematic review. *BJOG* 2021;128:366-74.
  13. Trigo L, Eixarch E, Bottura I, Dalaqua M, Barbosa AA, De Catte L, *et al.* Prevalence of supratentorial anomalies assessed by magnetic resonance imaging in fetuses with open spina bifida. *Ultrasound Obstet Gynecol* 2022;59:804-12.
  14. Kamalammal R, Lingappa S, Rajalu P. Cervical meningocele with tethered cord. *Int J Contemp Pediatr* 2016;3:1132-4.
  15. McLone DG, Naidich TP. Terminal myelocystocele. *Neurosurgery* 1985;16:36-43.
  16. Pang D, Dias MS. Cervical myelomeningoceles. *Neurosurgery* 1993;33:363-72.
  17. Salomão JF, Cavalheiro S, Matushita H, Leibinger RD, Bellas AR, Vanazzi E, *et al.* Cystic spinal dysraphism of the cervical and upper thoracic region. *Childs Nerv Syst* 2006;22:234-42.
  18. Tortori-Donati P, Rossi A, Cama A. Spinal dysraphism: A review of neuroradiological features with embryological correlations and proposal for a new classification. *Neuroradiology* 2000;42:471-91.
  19. Habibi Z, Nejat F, Tajik P, Kazmi SS, Kajbafzadeh AM. Cervical myelomeningocele. *Neurosurgery* 2006;58:1168-75.
  20. Feltes CH, Fountas KN, Dimopoulos VG, Eскурра AI, Boev A, Kapsalaki EZ, *et al.* Cervical meningocele in association with spinal abnormalities. *Childs Nerv Syst* 2004;20:357-61.
  21. Chiapparini L, Saletti V, Solero CL, Bruzzzone MG, Valentini LG. Neuroradiological diagnosis of Chiari malformations. *Neurol Sci* 2011;32 Suppl 3:S283-6.
  22. Pessoa BL, Lima Y, Orsini M. True cervicothoracic meningocele: A rare and benign condition. *Neurol Int* 2015;7:6079.
  23. Lotfi M, Iranpour P, As'adi K. Cervical meningocele associated with subependymal nodular heterotopia. *Clin Imaging* 2011;35:214-6.
  24. Delashaw JB, Park TS, Cail WM, Vollmer DG. Cervical meningocele and associated spinal anomalies. *Childs Nerv Syst* 1987;3:165-9.
  25. Brokinkel B, Wiebe K, Hesselmann V, Filler TJ, Ewelt C, Müller-Hofstede C, *et al.* Surgical treatment in a patient with Klippel-Feil syndrome and anterior cervical meningocele: A case report and review of literature. *Eur Spine J* 2013;22 Suppl 3:S517-20.
  26. Kumar A, Mehrotra A, Verma PK, Das KK, Jaiswal AK, Behari S. Anterior cervical meningocele with craniovertebral junction instability – A case report and literature review. *J Craniovertebr Junction Spine* 2021;12:440-4.
  27. Srihari G, Basappa HS, Kumar BV, Harish PN. Anterior cervical meningocele in a neonate. *Neurol India* 2013;61:692-3.
  28. Shore RM, Chun RW, Strother CM. Lateral cervical meningocele. *Clin Pediatr (Phila)* 1982;21:430-3.
  29. Morvan T, de Broucker F, de Broucker T. Subarachnoid hemorrhage in neurofibromatosis type 1: Case report of extracranial cerebral aneurysm rupture into a meningocele. *J Neurosurg* 2011;38:125-8.
  30. Osaka K, Tanimura T, Hirayama A, Matsumoto S. Myelomeningocele before birth. *J Neurosurg* 1978;49:711-24.
  31. Paschereit F, Schindelmann KH, Hummel M, Schneider J, Stoltenburg-Didinger G, Kaendl AM. Cerebral abnormalities in spina bifida: A neuropathological study. *Pediatr Dev Pathol* 2022;25:107-23.
  32. Bhargava R, Hammond DI, Benzie RJ, Carlos E, Ventureyra G, Higgins MJ, *et al.* Prenatal demonstration of a cervical myelocystocele. *Prenat Diagn* 1992;12:653-9.
  33. Kirbas A, Danisman N. A case of cervical meningocele. 13<sup>TH</sup> World Congress of Fetal Medicine 2014-Nice, France; 2015.
  34. Shamji MF, Ibrahim A. Images in clinical medicine. Cervical meningocele. *N Engl J Med* 2015;373:e4.
  35. Pérez LM, Wilbanks JT, Joseph DB, Oakes WJ. Urological outcome of patients with cervical and upper thoracic myelomeningocele. *J Urol* 2000;164:962-4.
  36. Meyer-Heim AD, Klein A, Boltshauser E. Cervical myelomeningocele – Follow-up of five patients. *Eur J Paediatr Neurol* 2003;7:407-12.
  37. Ali MZ. Cystic spinal dysraphism of the cervical region: Experience with eight cases including double cervical and lumbosacral meningoceles. *Pediatr Neurosurg* 2010;46:29-33.
  38. Nejat F, Habibi Z, Khashab ME. True myelomeningocele with exposed placode: Unusual presentation of cervical myelomeningocele. *J Neurosurg Pediatr* 2010;5:454.